

# Management of Mandibular Body Fracture in an Eighteen-Month-Old Child - A Case Report

Samson Jimson<sup>1\*</sup>, Cakku Jalliah Venkatakrishnan<sup>2</sup>, Bhanumurthy Lokesh<sup>1</sup> and Jacob Mathew Philip<sup>2</sup>

## KEYWORDS

Body of mandible, child, facial injury, fracture, mandible

## ABSTRACT

With the advancement of the transportation system and improvement in road conditions, the number of high-velocity accidents has also increased. Almost all of these reported cases involve individuals who had travelled in vehicles without adhering to personal protection standards and with rash driving. Injuries to the facial region can be profoundly disturbing and particularly in children. Parents find it very distressing to see their child in pain with a disfigured or injured face. It is difficult to manage such crying & sometimes uncontrollable children. The most commonly injured facial bones are Nasal, Zygomatic and the Mandible. The incidence of facial bone fracture in children is uncommon, and we present a case report of an 18-month old child with a history of road traffic accident and swelling on the right side of the face. Intraoral examination shows limited mouth opening with submucosal ecchymosis in the right buccal mucosa and based on clinical and computed tomographic scan working diagnosis of fracture in the right body of the mandible was arrived. The child was treated with the circum-mandibular wiring to stabilize the mandibular fracture under general anaesthesia. After three weeks the splint was removed. The injury healed without complications in the post-operative period.

## INTRODUCTION

Facial trauma in children is somewhat uncommon and ranges from 0.6 % to 1.2 % of all fractures. Dentoalveolar injuries are more common in paediatric case [1]. In paediatric mandibular fracture condyle and the angle of the mandible are among the most commonly injured sites. Symphysis and para-symphysis are also common sites of injury. But comparatively injury to the body of the mandible is uncommon. Road traffic accidents, interpersonal violence and sports injuries are the primary causes of facial fractures in paediatric patients. Facial fractures in children can be

distressing to the parents and relatives [2]. Various protocol that should be taken into consideration before we start treating the paediatric case. The utmost priority being the growth potential and the developing dentition [3]. We discuss below the management of an 18-month-old male child who was brought to our hospital centre with a fractured body of the mandible.

## CASE HISTORY

### Aim

Aim of the case report is to diagnosis and management of an 18-month old male child with a fractured body of the mandible.

An 18-month-old male child with a history of road traffic accident (RTA) was brought to the outpatient Department of Oral and Maxillofacial Surgery by the parents. His parents were also victims of the same road traffic accident.

<sup>1</sup>Department of Oral & Maxillofacial Surgery, Tagore Dental College & Hospital, Tamil Nadu 600127, India.

<sup>2</sup>Department of Prosthodontics, Tagore Dental College & Hospital, Tamil Nadu 6200127, India.

\*Correspondence: jimsons@tagoredch.in

## Detailed History

The road traffic accident took place during the early hours of the morning when the victims (parents and the injured child) were travelling in a bus. As the bus was going towards its destination on the national highway, the driver of the bus had to stop the bus suddenly to prevent a collision with another vehicle that was parked on the highway. The sudden stoppage of the bus led to their positioning of passengers into the front region of the bus. The parents sustained injuries in other parts of the body, while the child had sustained injuries in the facial region. Patient's Glasgow coma scale revealed 15/15, unaltered gait, well oriented to time and place, moderately built and moderately nourished.

Our colleagues in the Tagore Medical College & Hospital, Department of Orthopaedics treated his mother for the injury in her leg.

## Extraoral Examination

Extraoral examination shows the presence of a swelling on the right side of the face near the lower jaw. The swelling extended anteriorly from the right corner of the mouth to right angle of the mandible (anteroposterior) and below the zygomatic arch up to the lower border of mandible (superoinferior). There was elicitable tenderness over the region of swelling on the right side of the face. There was limited mouth opening because of pain and muscle spasm.

## Intraoral examination

Intraoral examination revealed submucosal ecchymosis in the right buccal mucosa

Towards the lower molar tooth region. The intraoral examination did not show any other positive clinical findings, other than an elicitable tenderness over the right side of lower jaw.

## Computed tomographic scan examination (CT)

Immediately following the RTA, the victims of the bus accident received initial first aid at a nearby Trauma centre. At this centre, computed tomographic scan examination (CT) was done for this patient. These computed tomographic scan films were brought to us. On review, it revealed a discontinuity in bone extending from the superior border to the inferior border of the right side body of the mandible.

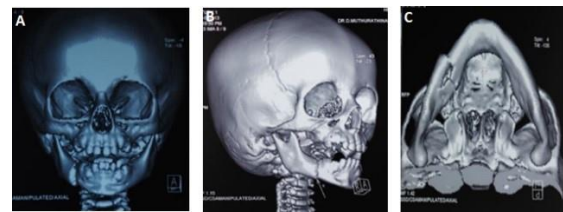
## Diagnosis

Based upon the clinical examination and computed tomographic scan images a working diagnosis of

compound fracture in the right body of the mandible was arrived at. (Figure1).

## Treatment plan

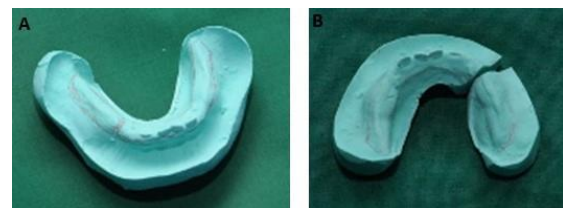
Based on the diagnosis, fracture of the right body of mandible, circum-mandibular wiring was planned under General anaesthesia. The circum-mandibular wiring was preferred as the ideal treatment option for this child considering: the age of the child, the physical condition of the traumatized child, their permanent tooth bud should not hamper and only the upper and lower anterior teeth were present.



**Figure 1.** The 3D volume rendered images of the paediatric patient.

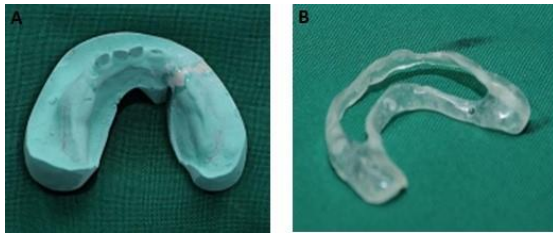
## Management

Under nasotracheal intubation, alginate impression of the lower jaw was made using a disposable stock tray by a Prosthodontist. A stone cast was made using type III gypsum product (Figure2A). The cast was trimmed to have a flat base. A surgical model of the fractured segments was simulated by sectioning the lower stone model using an axe saw at the site of a fracture. The two fractured segments were repositioned to the desired normal anatomic position (Figure 2B).



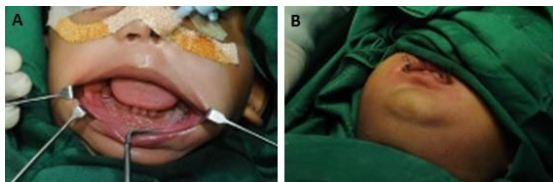**Figure 2.** Preoperative study models.

The segments were stabilized in this position using sticky wax, and the resulting defect was filled with quick setting plaster. It was arbitrarily shaped to provide continuity between the two segments (Figure 3A). An acrylic cap splint was then processed on the model by the Prosthodontist using auto-polymerizing acrylic resin (Figure 3B). Holes were drilled in the cap splint using 1 mm diameter straight fissure bur to facilitate the passage of 26-gauge wire for circum-mandibular wiring.



**Figure 3.** Fracture line simulated and splint fabricated.

An extra-oral stab incision was placed in the lower border of the mandible, and a surgical awl was passed along the buccal surface through the extraoral stab incision. A stainless steel 26-gauge wire was passed through the awl and reinserted along the lingual surface. The same procedure was carried out on the opposite side of the mandible. The fractured segments were then reduced anatomically under the guidance of the surgical splint. With the acrylic splint in position over the teeth and ridge, the stabilization of the acrylic splint was done using the inserted 26-gauge stainless steel wire. (Figure 4). Haemostasis was achieved, and the general anaesthetic recovery of the child was uneventful. The child was well cooperative tolerated the pain and was taken care meticulously in the post-operative child-care ward. As the post-operative period was uneventful, the child was discharged after 2 days. The child was prescribed Antibiotics and Analgesics for 5 days. (Amoxicillin suspension and Paracetamol).



**Figure 4.** Intraoperative image showing the splint in final position.

After 3 weeks, in the post-operative review period, the surgical splint was removed in the operating room under sedation. The procedure was uneventful, and the child recovered well. Thereafter the parents did not bring the child for regular review appointments. After 12 months, when they came, and the review examination of the child showed healthy healing of the surgical site with no obvious discrepancy.

## DISCUSSION

The incidence of facial bone fractures in paediatric patients is rare when compared to its prevalence in adult patients [4]. This might be because in infants there is flexibility of the facial bone, lack of

pneumatization of the Para Nasal Sinus and the protection of the malar region by the prominent buccal fat pad [5]. It is to be noted that the ratio between the cranial and facial volume is 8:1 at birth and 2.5:1 when the growth is completed. The relative position of the skull to the facial bone and the retruded position of the midface & mandible in children are the reasons that reduce the incidence of facial fracture [6].

Fracture of the body of the mandible is less common when compared to other common sites for paediatric mandibular fractures such as the condyles, sub condylar region, and the angle of the mandible. The symphysis and Para symphysis regions are the next commonly injured sites in the paediatric mandible. Male children are more often involved. Motor traffic accidents come first in order followed by domestic violence as a reason for these fractures [7]. Lot of factors like age, site, growth and development of the child should be taken into consideration while planning the treatment. These factors will decide the surgical approach for the child [8].

Facial fractures in children are often overlooked if there are no obvious external injuries. In our case, there was no apparent injury to the face except for swelling on the side of trauma. This led to the suspicion of fracture thereby leading to the diagnosis following CT film review [6].

There are different modalities of treating a paediatric mandible. It includes open reduction and internal fixation (ORIF), closed reduction and inter maxillary fixation (IMF), open reduction with intraosseous wiring [9].

However, there are limitations to every treatment modality. Many maxillofacial surgeons use ORIF to fix fractures in children [10]. ORIF can lead to damage to the developing tooth, and if stainless steel mini plates are used, it will require a second surgery to remove the mini plates. Resorbable plates can be used, but the thickness of the plate may be of some concern [9,11]. The strength of the resorbable plates was in question and was reported that it could not be used in mandibular fractures. However, with self-reinforcing techniques, the strength of the screws and plates has been improved and can be used in high load sites [2]. Rigid internal fixation might not be required, as any mild discrepancy in the occlusion will get corrected spontaneously as the permanent teeth erupt.

Condylar fractures, however, require a different approach. It might require inter-maxillary fixation of a short duration [2]. Longer duration of IMF can

lead to ankylosis and retarded mandibular growth. There are some limitations in the use of IMF as the inability to use in children where all primary teeth have not erupted and in mixed dentition stage. This was the case where the child was only 18 months old [3]. Children do not like their mouth be tied, as it will be an uncomfortable situation for them to manage their daily routine.

According to Defabianis, orthogonal restoration of occlusion for a correct transfer of forces through the maxilla to the rest of the cranial bones is required for proper facial development. He has suggested functional appliance to achieve this [8].

Circum-mandibular wiring with an acrylic splint seems to be a safe and easy option of fixation in young children. There is a new technique that was advocated by Thomas for atraumatic placement of wires in the circum-mandibular wiring [12]. However, we followed the conventional technique by using the awl to pass the wire around the buccal and lingual cortices.

Postoperative complications following paediatric facial fractures are rare. However, research indicates that a complication like TMJ ankylosis 1-7% among all condylar fractures. This increases when there is a bilateral condylar fracture. There can be facial asymmetry as a result of the asymmetrical growth of the mandible.

Nasal deformity following nasal trauma is another occurrence, which will require secondary rhinoplasty after the cessation of growth.

In the treatment of paediatric mandibular fractures between the age of 2-5years having an established deciduous dentition makes the conical shaped teeth eligible only for interdental wiring Arch bar wiring cannot be considered as a treatment option due to the difficulty in securing them at the gingival margin level. Resin-stabilized Mini arch bar can be used for the treatment of undisplaced mandibular fractures.

## REFERENCES

1. Adlakha V, Chandna P, Bansal V, Agarwal A. Mandibular fracture in an 18-month-old child. *Indian J Dent Res.* 2011;22(5):723-725.
2. Yerit K, Hainich S, Enislidis G, Turhani D, Klug C, Wittwer G et al. Biodegradable fixation of mandibular fractures in children: Stability and early results. *Oral Surg Oral Med, Oral Pathol Oral Radiol Endod.* 2005;100(1):17-24.
3. Hegab A. Management of mandibular fractures in children with a split acrylic splint: a case series. *Br J Oral Maxillofac Surg.* 2012;50(6):e93-e95.

In children aged 6-12 years, during the mixed dentition period, dental stability should be taken care. The deciduous molars can be used for fixation between the age of 5-8years. In children of age between 7-11 years, the primary molars and incisors can be used as the anchor. In children of age 9- 12 years, intermaxillary fixation with arch bars can be done using the permanent dentition.

In fact, there is the absence of an established dentition in children below 2 years; such can be counted as edentulous. Hence the circummandibular wire stabilization with acrylic splints (Mono mandibular) fixation in children remains the effective method of managing mandibular fracture in paediatric patients below the age of 2 years.

## CONCLUSION

According to our aim of our case report we have managed the 18-month-old child with circummandibular wiring under general anaesthesia. A closed method approach in reducing the fractured segments and circum-mandibular wire stabilization with acrylic splints (Mono-mandibular) fixation can be considered as a valuable treatment choice in managing mandibular fractures in paediatric trauma patients.

## ACKNOWLEDGEMENT

The author would like to thank Dr. Chitraa R.Chandran, Principal, Tagore Dental College & Hospital and Dr. Sree Ranjani from Department of Anaesthesiology, Tagore Medical College & Hospital for all their assistance with regards to the procedure.

## DECLARATION OF INTEREST

The authors report no conflicts of interest. The authors alone are responsible with the content of this article.

4. Anderson P, David D. Hyperostosis as a late sequel of parasymphyseal mandibular fractures in 2 children. *J Craniomaxillofac Surg.* 2005;33(3):188-190.
5. Eggensperger Wymann N, Hölzle A, Zachariou Z, Iizuka T. Pediatric Craniofacial Trauma. *J Oral Maxillofac Surg.* 2008;66(1):58-64.
6. Zimmermann C, Troulis M, Kaban L. Pediatric facial fractures: recent advances in prevention, diagnosis and management. *Int J Oral Maxillofac Surg.* 2006;35(1):2-13.
7. Choi J, Oh N, Kim I. A follow-up study of condyle fracture in children. *Int J Oral Maxillofac Surg.* 2005;34(8):851-858.
8. Zhao Y, Yang J, Bai R, Ge L, Zhang Y. A retrospective study of using removable occlusal splint in the treatment of condylar fracture in children. *J Craniomaxillofac Surg.* 2014;42(7):1078-1082.
9. Wu Y, Long X, Fang W, Li B, Cheng Y, Deng M et al. Management of paediatric mandibular condylar fractures with screw-based semi-rigid intermaxillary fixation. *Int J Oral Maxillofac Surg.* 2012;41(1):55-60.
10. Iatrou I, Theologie-Lygidakis N, Tzerbos F. Surgical protocols and outcome for the treatment of maxillofacial fractures in children: 9 years' experience. *J Craniomaxillofac Surg.* 2010;38(7):511-516.
11. Li Z, David O, Li Z. The use of resorbable plates in association with dental arch stabilization in the treatment of mandibular fractures in children. *J Craniomaxillofac Surg.* 2014;42(5):548-551.
12. Thomas S, Yuvaraj V. Atraumatic placement of circummandibular wires: A technical note. *Int J Oral Maxillofac Surg.* 2010;39(1):83-85.

**Editorial History**

Date of Submission: 17092019

Review and Revision: 05112019 to 18122019

Accepted: 08012020

Published: 29012020

License Information: This work is licensed under a Creative Commons Attribution